

# World's First Experience Treating TASC II C and D Tibial Occlusive Disease Using the Selution SLR Sirolimus-Eluting Balloon: Six-Month Results From the PRESTIGE Study

Tjun Yip Tang, MA (Cantab), MB BChir, MD, FRCS, FAMS<sup>1,2</sup>,  
 Charyl Yap, BSc (Hons)<sup>1</sup> , Shereen Xue Yun Soon, BSc (Hons)<sup>1</sup> ,  
 Sze Ling Chan, BSc (Pharm)(Hons), PhD<sup>3</sup> ,  
 QingWei Shaun Lee, MBBS, MMed, FRCS<sup>1</sup>, Hao Yun Yap, MBBS, MMed, FRCS<sup>1</sup>,  
 Hsien Ts'ung Luke Tay, MBBS, MSc, MMed, FRCS<sup>1</sup> ,  
 and Tze Tec Chong, MBBS, FACS, RPVI<sup>1</sup>

## Abstract

**Purpose:** The performance of sirolimus-coated devices has not been studied in patients with chronic limb-threatening ischemia patients. PRESTIGE aims to investigate the 6-month efficacy and safety profile of the Selution Sustained Limus Release (SLR) sirolimus-eluting balloon for treatment of TASC II C and D tibial occlusive lesions in patients with CLTI. **Materials and Methods:** PRESTIGE is a pilot prospective, nonrandomized, single-arm, multi-investigator, single-center clinical study. Endpoints were adverse event-free survival at 1 month, technical success rate, primary tibial patency at 6 months, limb salvage success, target lesion revascularization (TLR), and amputation free survival (AFS). **Results:** A total of 25 patients were included. There were 17 (68.0%) males; mean age, 63.7±9.73 years. CLTI severity was based on the Rutherford scale (R5=25/25; 100.0%). Significant comorbidities included diabetes mellitus (n=22; 88.0%) and end-stage renal failure (n=11; 44.0%). A total of 33 atherosclerotic lesions were treated (TASC II D=15 (45.5%)). Mean lesion length treated was 191±111 mm. Technical success was 100%. Primary tibial patency at 6 months was 22/27 (81.5%) and freedom from clinically driven TLR was 25/30 (83.3%). AFS was 21/25 (84.0%; 3 deaths and 1 major lower extremity amputation). Mean Rutherford score improved from 5.00 at baseline to 1.14±2.10 (p<0.05) at 6 months. There was a wound healing rate of 13/22 (59.1%) and 17/21 (81.0%) at 3 and 6 months respectively. **Conclusions:** Selution SLR drug-eluting balloon is a safe and efficacious modality in treating complex tibial arterial occlusive lesions in what is an otherwise frail cohort of CLTI patients, with a high prevalence of diabetes and end-stage renal failure. Technical and clinical success rates are high and 6-month target lesion patency and AFS are more than satisfactory.

## Keywords

sirolimus, drug-coated balloon, Selution SLR, percutaneous angioplasty, chronic limb threatening ischemia, limb salvage, wound healing, outcome

## Introduction

Peripheral arterial disease (PAD) is the atherosclerotic occlusive disease of the lower extremity arteries and afflicts hundreds of millions of individuals worldwide.<sup>1</sup> Its most severe manifestation is chronic limb-threatening ischemia (CLTI), which is defined by the presence of ischemic rest pain, lower limb ulceration, or gangrene for more than 2 weeks' duration.<sup>2</sup> Patients with CLTI usually present with multilevel infra-inguinal PAD and tibial arterial occlusions.<sup>2</sup> An endovascular-first revascularization policy

using percutaneous angioplasty (PTA) is currently preferred to reestablish straight-line blood flow to the foot.<sup>3</sup> Despite an excellent technical success rate (>90%), tibial

<sup>1</sup>Department of Vascular Surgery, Singapore General Hospital, Singapore

<sup>2</sup>Duke-NUS Graduate Medical School, Singapore

<sup>3</sup>Health Services Research Center, SingHealth, Singapore

### Corresponding Author:

Tjun Yip Tang, Department of Vascular Surgery, Singapore General Hospital, Level 5, Academia, 20 College Road, 169856, Singapore.  
 Email: tang.tjun.yip@singhealth.com.sg

angioplasty is plagued by high incidence of restenosis because of vessel wall elastic recoil<sup>4</sup> and barotrauma caused by the intra-arterial ballooning process, which leads to neointimal hyperplasia (NIH).<sup>5</sup> Elastic recoil occurs within 15 to 30 minutes after balloon angioplasty and may account for up to 50% reduction of the acute luminal gain and this is attributed to contraction of the elastic lamina of the arterial wall.<sup>6</sup> Current options of countering recoil include prolonged inflation with a larger diameter balloon or stent implantation.<sup>7</sup> Tibial vessel renarrowing accounts for clinically indicated target lesion revascularization (TLR), which can be as high as 48% at 12 months<sup>8</sup> and increases morbidity in the CLTI setting.<sup>6</sup>

Devices coated with paclitaxel and rapamycin analogues such as sirolimus and everolimus have been used successfully to limit restenosis by inhibiting the biologic pathway that leads to NIH.<sup>9</sup> Effects of rapamycin analogues have been well-studied in the coronary circulation, where sirolimus-eluting stents have been shown to be safe and more effective than paclitaxel devices.<sup>10</sup> The drug is generally perceived by cardiologists as superior to paclitaxel because of lower restenosis rates in the coronary bed following sirolimus- vs paclitaxel-eluting stents, with a wider therapeutic window and a higher safety margin.<sup>11</sup> It is well accepted, however, that paclitaxel-coated balloons or stents achieve better outcomes than conventional balloon angioplasty (CBA) in terms of long-term angiographic (patency rate, late lumen loss) and clinical results (TLR and device-related events) in the peripheral vasculature.<sup>12,13</sup> However, recent attention has been drawn to a possible increase in late mortality in the setting of intermittent claudication<sup>14</sup> and lower amputation-free survival (AFS) (but not mortality per se)<sup>15</sup> in CLTI patients, receiving paclitaxel-coated devices for PAD.

Small tibial artery diameters, especially relevant to the Asian population vessels, and poor luminal gain post tibial angioplasty contribute in part to poor patency rates.<sup>16</sup> Early elastic recoil is an Achilles heel<sup>4</sup> in patients with CLTI because their crural occlusive lesions are often long, calcified, and recalcitrant to ballooning. Drug-coated technology may have the potential to minimize NIH response, but their role in addressing the problem of acute recoil is probably nominal at best.<sup>16</sup> Optimal vessel preparation with prolonged angioplasty using long balloons, optimal balloon sizing, and appropriate assessment and treatment of medial wall calcification and post angioplasty dissections can lower restenotic phenomenon due to elastic recoil and achieve better luminal gain.<sup>7</sup>

The aim of this study was to evaluate the 6-month safety and performance outcomes of the Selution SLR (M. A. MedAlliance SA, Nyon, Switzerland) sirolimus-coated balloon, for the treatment of complex tibial occlusive lesions [TransAtlantic InterSociety Consensus (TASC) C and D] in Asian patients with CLTI.

## Materials and Methods

### PRESTIGE Study Design

In the Physician-initiated, prospective, non-Randomized single-center, single arm, multi-investigator trial investigating the safety and Efficacy of the treatment with the Selution Sustained Limus Release Sirolimus Coated Balloon in TASC II C and D Tibial occlusive disease in patients with chronic limb threatening Ischemia (PRESTIGE) study (NCT04071782), Selution SLR was studied for the treatment of complex tibial artery occlusive disease in CLTI patients from a multiethnic Asian cohort.<sup>17</sup> Clinical primary safety endpoint was freedom from major adverse clinical events (MACE), a composite of freedom from device- and procedure-related mortality through 30 days. Performance primary endpoint was freedom from clinically driven TLR within 6 months post-index procedure. Clinically-driven TLR was defined as any reintervention performed for  $\geq 50\%$  diameter stenosis (on duplex ultrasound) at the target lesion with a clinical need such as delay in wound healing.

Secondary endpoints included the following:

1. Primary patency rate at 6- and 12-month follow-up; defined as absence of a hemodynamically significant stenosis on duplex ultrasound (peak systolic velocity ratio no greater than 2.5) at the target lesion and without TLR within the time of procedure and follow-up.
2. Technical success was defined as the ability to cross and dilate the lesion and achieve residual angiographic stenosis no greater than 30%.
3. Freedom from clinically-driven TLR at 12-month follow-up; defined as a repeat intervention to maintain or reestablish patency within the region of the treated arterial vessel plus 5 mm proximal and distal to the treated lesion edge.
4. Clinical success was defined as an improvement of Rutherford score<sup>18</sup> at all follow-up time points of one class or more as compared with baseline.
5. Wound healing at 6 months defined as closure of the primary wound by  $>75\%$ .
6. Freedom from major target limb amputation within 6 and 12 months post-index procedure.

The study was conducted in accordance with good clinical practice standards and the ethical principles of the Declaration of Helsinki. The local institutional review board approved this study (CIRB number: 2019/2121). Informed consent was obtained in accordance with institutional protocol from each patient undergoing PTA between November 2019 and January 2020 at a local tertiary vascular center experienced in diabetic foot salvage. The center

performs approximately 900 lower limb angioplasty interventions annually; majority (95% cases) for CLTI.<sup>19</sup> Patient demographics, comorbidities, tissue loss severity based on the Rutherford scale<sup>18</sup> were prospectively collected into a case report file. Procedural data of interest were TASC II lesion severity,<sup>20</sup> number of tibials treated, and tibial wall calcification severity. Lesion calcification was graded according to the presence of radio-opacities within the arterial wall at the site of occlusion or stenosis as per Dattilo et al.<sup>21</sup>

### *Inclusion/Exclusion Criteria*

Patients eligible for this study were  $\geq 21$  years of age, and had a documented diagnosis of CLTI, presenting with a score from 4 to 6 by Rutherford classification.<sup>18</sup> Patients had to have a projected life expectancy of at least 12 months and be compliant to the study protocol. Angiographic inclusion criteria included de novo and post-PTA restenotic lesions located in the tibial arteries, target lesion length was  $> 100$  mm and/or considered as TASC II C or D lesion according to the TASC II classification and the target lesion had angiographic evidence of stenosis  $> 50\%$  or occlusion, which had been passed with standard guidewire manipulation and predilated to  $< 30\%$  residual stenosis using prolonged CBA (3 minutes) prior to enrolment and without spiral dissections causing impairment in blood flow down the tibial artery. No other adjunctive devices were allowed to prepare the lesion (eg, scoring balloon and atherectomy device). Target vessel diameter had to be visually estimated  $> 1.5$  mm and  $< 4.0$  mm below the knee, although this was not formally measured. A maximum of 2 tibial arteries were treated. Lesions in the treated segment were continuous or had gaps present between stenoses and occlusions. Any tibial vessel intervened on must have had distal reconstitution above the ankle even if there was inframalleolar disease present. Inflow lesions (iliac, superficial femoral, and popliteal) had to be treated first with CBA with resulting  $< 30\%$  residual stenosis and no evidence of embolization, before tibial lesions could be addressed.

Exclusion criteria were any prior vascular surgery of the index limb, patient was permanently wheelchair bound or bedridden, and the intervention was being performed in preparation for a planned major lower limb amputation. Also, patients for whom antiplatelet therapy, anticoagulants or thrombolytic drugs were contraindicated or had an uncorrected bleeding disorder, untreatable lesion located at the distal outflow arteries, aneurysm located at the level of the superficial femoral/popliteal artery, nonatherosclerotic disease resulting in occlusion (eg, embolism, Buerger's disease, vasculitis), active septicemia and episode of acute limb ischemia within the previous month were excluded. Patients with previous hypersensitivity or

known contraindication to heparin, sirolimus, or contrast media were also not enrolled.

### *Selution SLR Sirolimus-Coated Balloon*

The Selution SLR DCB (CE marked February 2020) consists of a standard PTA balloon catheter coated with sirolimus, at a dose density of  $1 \mu\text{g}/\text{mm}^2$ . The drug coating utilizes micro-reservoirs made out of a biodegradable polymer (poly(lactic-co-glycolic acid) or PLGA microspheres) suspended in a phospholipid blend and are coated onto the balloon with a proprietary Cell Adherent Technology amphipathic transfer membrane that contains and protects them during balloon insertion, lesion crossing, and inflation. During balloon inflation, the transfer membrane containing the micro-reservoirs releases from the balloon surface and adheres to the vessel lumen. The use of a solid sirolimus solution in PLGA microspheres allows for sustained release drug delivery into the vessel wall as the small drug molecule diffuses through the polymer network. The balloon catheter is an over-the-wire 0.018-inch guidewire device. Angioplasty balloon diameters of 2 to 4 mm and 150 mm lengths were available for PRESTIGE.

### *Procedure*

The senior authors (TYT/TTC) performed all PTA interventions in a dedicated vascular hybrid operating theatre either under local, regional, or general anesthetic depending on patient compliance, procedure complexity, and whether a concomitant wound debridement or digital amputation were also required. Attempt to perform intraluminal crossing of the stenosis or occlusion was preferred but a low threshold to convert to a subintimal crossing technique was taken, especially in the more calcified occluded lesions. A retrograde SAFARI approach was performed in the case of failure to cross from an antegrade position. PTA with noncompliant high-pressure or semicompliant balloons was used invariably to both supra- and infrapopliteal lesions for 180 seconds for vessel preparation. In the absence of significant recoil or flow-limiting dissection from the following angiogram, subjects were enrolled into the study. The Selution SLR balloon was typically inflated for up to 2 minutes to maximize drug transfer to the vessel wall. Balloon length was selected to include at least 10 mm of normal artery proximal and distal to the lesion to ensure that the lesion was fully covered and the size of the balloon was selected to a 1:1 sizing ratio to the normal artery segment diameter. If 2 devices were required to cover the lesion, the specified balloon overlap was at least 10 mm. For residual stenosis  $> 30\%$  or flow-limiting dissection after use of the first Selution SLR drug-eluting balloon (DEB), use of a second device, inflated for 4 minutes, was allowed in the affected area. Use of CBA post sirolimus elution was not

allowed because it can potentially dislodge the micro-reservoirs, reducing the effectiveness of the device. If residual stenosis remained >30% or if flow-limiting dissection persisted after use of a second investigational device, the treatment was left to physician discretion, but implantation of a drug eluting stent was used as a bailout solution.

### Adjuvant Medical Therapy

Postprocedure, all subjects received daily dose aspirin (100 mg) and clopidogrel (75 mg) orally for at least 3 months, followed by treatment with aspirin alone.

### Follow-up

Clinical progress and wound healing were monitored at 1, 3, and 6 months. A 6-month duplex ultrasound was performed to check tibial artery patency (Figure 1). Quality of life survey in the form of the EQ5D<sup>22</sup> and a Walking Impairment Questionnaire (WIQ)<sup>23</sup> were administered at each time point.

### Statistical Analysis

Baseline variables were summarized with the use of descriptive statistics. Mean and standard deviation or median and range, where appropriate, were used to describe continuous variables. Categorical variables were presented as absolute number and percentage. For TLR, amputation of the same limb or death were competing events that would preclude TLR, therefore the cumulative incidence of TLR was estimated from competing risks data using the *cmprsk* package in R. For AFS and death, the survival probability was estimated using Kaplan-Meier analysis. To evaluate the changes in EQ5D scores and parameters such as walking distance and stairs use from the WIQ over time, linear mixed models were fitted, which account for patient-level correlations between repeated measurements. R version 3.5.1<sup>24</sup> was used to perform all the analyses.

## Results

### Patient Demographics

A total of 25 patients were enrolled over a 2.5-month period. A total of 17 of 25 (68.0%) patients were male and mean age was 63.7±9.7 years. Twenty-two of 25 (88%) patients had diabetes mellitus and 11/25 (44.0%) had end-stage renal failure (ESRF). The majority were American Society of Anesthesiologists (ASA) grade 3 and above [22/25 (88%)]. All patients had some degree of tissue loss [Rutherford category 5 = 25/25 (100%)] and mean presenting Wifl (wound, ischemia, foot infection)<sup>25</sup> score was 3.72±1.14. Using the Society for Vascular Surgery clinical

stages by expert consensus,<sup>25</sup> 14/25 (56.0%) limbs were at high or moderate risk of major amputation at 1 year. Table 1 shows the subject demographics.

### Lesion Characteristics

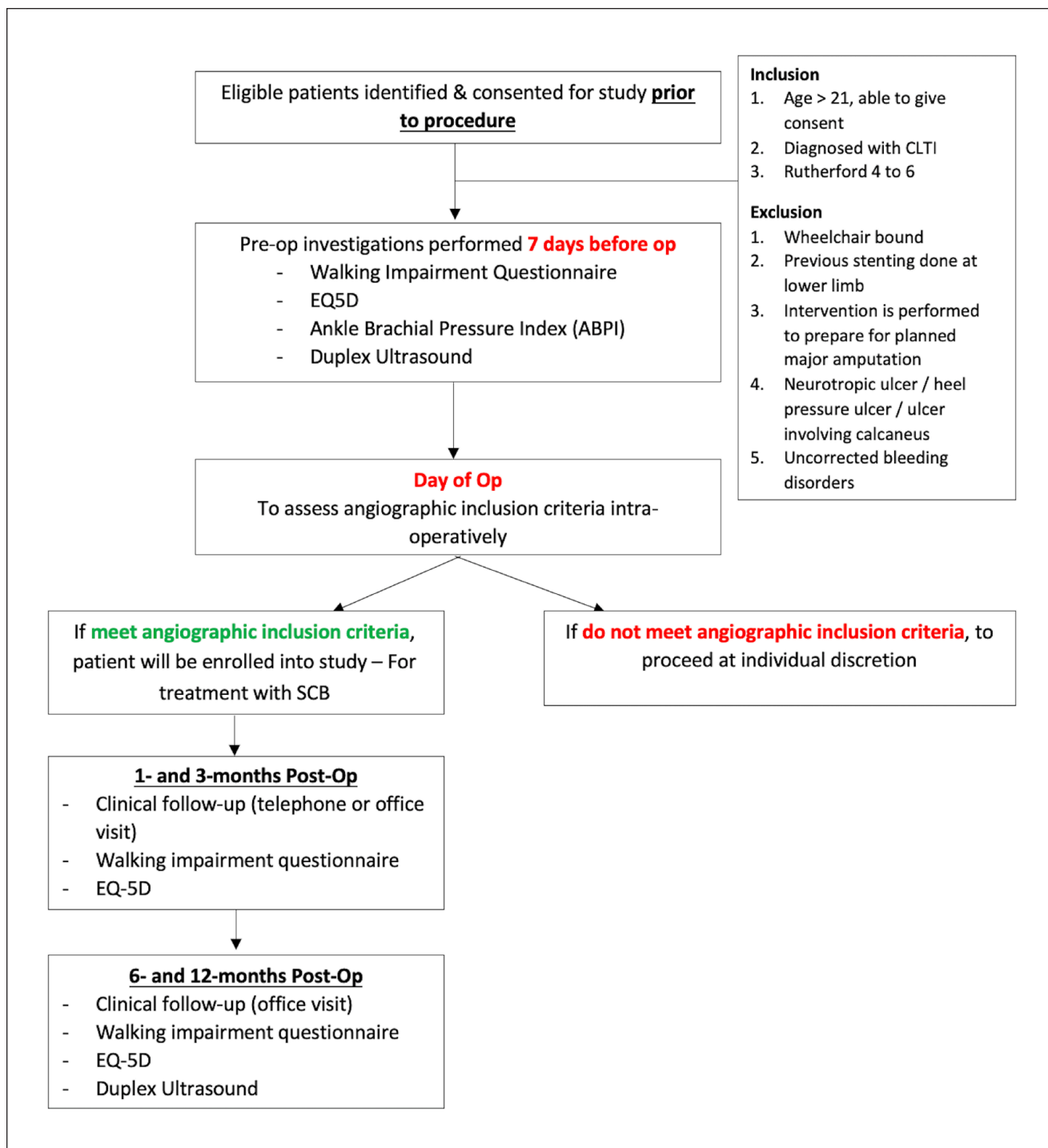
Twenty-five legs (33 tibial lesions; 21 de novo and 12 restenosis) were treated. A total of 15 of 33 (45.5%) were TASC II D lesions. Mean lesion length treated was 19.1±11.1 cm. The anterior tibial artery (ATA) was the most treated tibial vessel [17 of 33 (51.5%)]. There was a high incidence of moderate to severe vessel wall calcification [21 of 33 (63.6%)].

Majority of patients [15 of 25 (60.0%)] had multilevel atherosclerotic disease below the groin. Inframalleolar disease was treated in 10 of 25 (40.0%) limbs. Table 2 shows lesion characteristics and procedural data.

### Outcomes

There was 100% technical success. There were no retained device components events or device-related deaths. Only 1 case was excluded because of severe recoil (>30%) prior to decision for enrolment. There was no slow flow phenomenon encountered after sirolimus elution even with the balloon placed below the ankle in significant number of cases (40%). No serious adverse events were reported during the first 30 days posttreatment.

The primary tibial patency at 3 months was 24 of 29 (82.8%) and freedom from clinically-driven TLR was 25/30 (83.3%). AFS at 3 months was 22/25 (88.0%) (2 deaths and 1 major lower extremity amputation). The primary tibial patency at 6 months was 22/27 (81.5%) and the freedom from clinically-driven TLR was 25/30 (83.3%). AFS was 21/25 (84%). The 3 causes of death were from septic shock from foot wound infection and 2 cases were from severe coronary heart disease. One below-knee amputation was performed for tracking sepsis up the shin. Despite tibial patency and evidence of primary wound healing, patient did not want to continue with wound salvage therapy. Cumulative incidence of TLR and survival probability for AFS and death are presented in Figure 2A and B, respectively. The mean Rutherford score at baseline was 5.00 and improved to 3.26±2.40 and 1.14±2.10 at 3 and 6 months, respectively. There was a wound healing rate of 13/22 (59.1%) and 17/21 (81.0%) at 3 and 6 months, respectively. Eighteen of 25 (81.8%) patients showed improvement by at least 1 Rutherford category by 6 months (Figure 3). There was a significant improvement in the EQ5D quality of life scores at 6 months compared to baseline (Figure 4A) and between 3 and 6 months on the EQ5D-visual analogue scale (VAS) score, which may be related to wound healing and regaining independence to ambulate again. In terms of the walking impairment score,



**Figure 1.** PRESTIGE Trial flow diagram.

there was significant improvement in walking distance between 1 and 3 months and between 1 and 6 months post-revascularization and again is likely to be related to the wound healing trajectory and being able to regain mobility (Figure 4B). Furthermore, there were significant improvements in walking speed scores across most of the follow-up

time points. Figure 5 shows a case of a plantar ulcer, with the lower limb undergoing an anterior tibial and peroneal angioplasty and Solutio SLR elution to both vessels. The wound had healed by 3 months and remained closed at 6 months. The 6-month duplex showed a good biphasic signal in the target vessels.

**Table 1.** Patient Demographics (Total Patients, N=25).

Characteristics	n (%)
Age, y, mean $\pm$ SD (range)	63.72 $\pm$ 9.73 (42–80)
BMI, kg/m <sup>2</sup> , mean $\pm$ SD	24.40 $\pm$ 4.88
Male gender	17 (68.0)
Ethnic group	
Chinese	18 (72.0)
Malay	4 (16.0)
Indian	3 (12.0)
Smoking status	
Smoker	5 (20.0)
Nonsmoker	16 (64.0)
Ex-smoker	4 (16.0)
Comorbidities	
Diabetes	22 (88.0)
Hypercholesterolemia	19 (76.0)
Hypertension	22 (88.0)
CVA in the past 12 months	1 (4.0)
Myocardial infarction	3 (12.0)
Angina	2 (8.0)
Congestive heart failure	4 (16.0)
ESRF	11 (44.0)
Medication history	
Aspirin	24 (96.0)
Clopidogrel	9 (36.0)
Anticoagulants	3 (12.0)
Statins	23 (92.0)
ACE inhibitors	10 (40.0)
Angiotensin receptor antagonists	8 (32.0)
Beta-blocker	13 (52.0)
Insulin	14 (56.0)
Oral diabetic medications	14 (56.0)
ASA scores	
2	3 (12.0)
3	21 (84.0)
4	1 (4.0)
Hemoglobin, g/dL	
<10	9 (36.0)
$\geq$ 10	16 (64.0)
Rutherford score 5	25 (100.0)
Wifl score, mean $\pm$ SD	3.72 $\pm$ 1.14
Toe pressure, mm Hg, median (range)	37.5 (0–100)

Abbreviations: ACE, angiotensin-converting enzyme; ASA, American Society of Anesthesiologists; BMI, body mass index; CVA, cardiovascular accident; ESRF, end-stage renal failure; Wifl, wound, ischemia, foot infection.

## Discussion

The novel data from PRESTIGE have shown that the use of the Soluton SLR DEB for infrapopliteal atherosclerotic disease after adequate lesion preparation with CBA is feasible, safe, and efficacious with no intraprocedural complications and no serious adverse events attributable to the technology through 1 month. In what is essentially an

all-comers pilot cohort with high rates of diabetes mellitus and ESRF, PRESTIGE has demonstrated a 100% technical success rate (100%) and a 6-month primary tibial patency of 81.5% and freedom from clinically-driven TLR of 83.3%. AFS was 84% and the mortality rate (12%) is in keeping with what is expected from a challenging and frail population of patients. Significant wound healing progress and improvement in ambulatory symptoms occurred with the Soluton SLR balloon through 6 months. A complete wound healing rate of 81% is comparable, if not superior, to an open bypass salvage strategy<sup>26</sup> and previously published data on the use of paclitaxel-coated balloon (PCB) rates in lower limb endovascular revascularization for tissue loss.<sup>2,27</sup>

PCB use in the infrapopliteal tibial vessels to minimize the restenosis effect from NIH remains controversial. Recent 6-months results from the Lutonix BTK trial showed noninferior 30-day safety profile and an improved primary efficacy endpoint in terms of lesion primary patency and AFS for infrapopliteal arterial lesions treated with PCB as compared with CBA, although it used complex Bayesian statistics to derive a final positive endpoint and their definition of primary patency was absence of occlusion rather than stenosis.<sup>28</sup> However, there were no statistical differences in efficacy beyond 6 months, with the Kaplan-Meier curves merging at 1 year. Furthermore, a recent network meta-analysis suggested that PCB had encouraging results in terms of primary patency and freedom from TLR compared with 4 other endovascular technologies in the setting of CLTI.<sup>29</sup> However, there are other meta-analyses that did not show superiority of PCB over CBA in terms of binary restenosis, TLR, and major amputation rates.<sup>30–32</sup> Furthermore, Katsanos et al<sup>15</sup> have recently showed a worse 1-year AFS rate following infrapopliteal arteries treated with PCBs, although this meta-analysis has been heavily criticized for use of nonpublished data at the time. AFS was worse in those studies using a higher dose (3.0–3.5  $\mu$ g/mm<sup>2</sup>) balloon drug coating and paclitaxel distal embolization was postulated to be the underlying mechanism by the authors. The amount of distal embolization with paclitaxel has been shown to be related to the drug dosage on the balloon and the type of excipient used.<sup>33</sup> This is usually seen as the “slow flow phenomenon” effect and is thought to be due to shedding of drug/excipient off the balloon during transfer to the arterial wall and is believed to be a potential cause of lower AFS with PCBs.<sup>15</sup> There was no reported distal embolization or “slow flow phenomenon” noticed, albeit subjective with no formal quantification, after application of Soluton SLR DEB even when the sirolimus coated balloon was inflated in the inframalleolar territory in a significant number of cases (40%). Another reason why there may have been a discrepancy in different meta-analysis findings in the efficacy of PCBs in the tibial vessels may be related to adequacy of lesion preparation between the studies included.<sup>32</sup> Literature describes favorable outcomes for

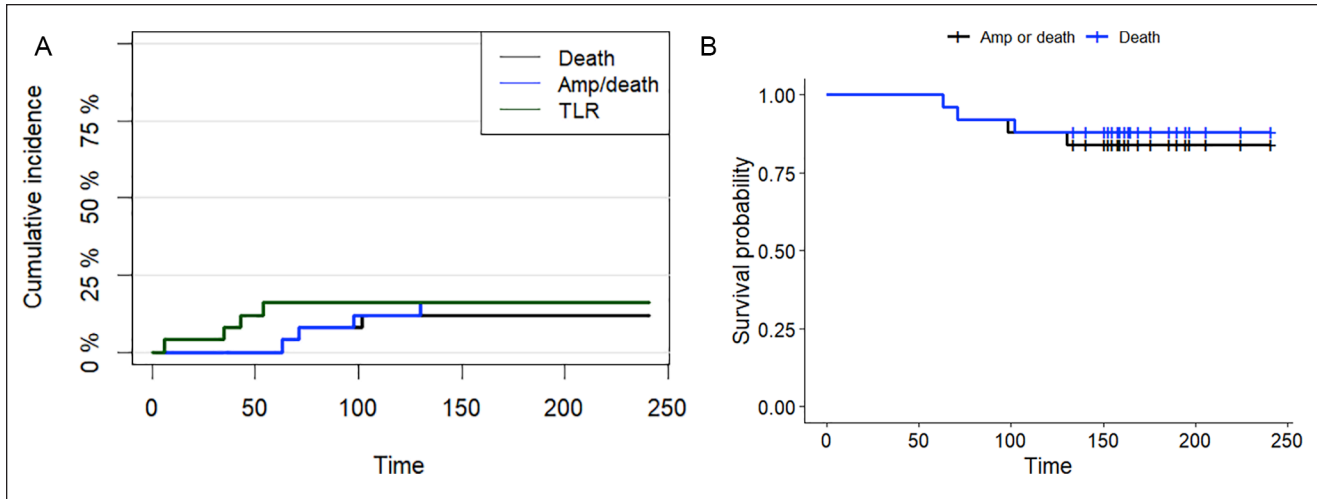
**Table 2.** Procedural and Lesion Details.

Characteristics	n (%)
Operative details	
Leg treated (n=25)	
Left	11 (44.0)
Right	14 (56.0)
Number of vessel runoff post-angioplasty	
1	9 (36.0)
2	13 (52.0)
3	3 (12.0)
Concomitant treatment of superficial femoral/popliteal artery	15 (60.0)
Concomitant treatment of inframalleolar disease	10 (40.0)
Bailout tibial stenting	0 (0.0)
SAFARI	1 (4.0)
Minor amputation	11 (44.0)
Lesion-specific details (n=33)	
Location of treated vessel (n=33)	
Anterior tibial artery	17 (51.5)
Posterior tibial artery	10 (30.3)
Common plantar artery	3 (9.1)
Dorsalis pedis artery	3 (9.1)
De novo	21 (63.6)
Restenotic	12 (36.4)
TASC classification	
C	18 (54.5)
D	15 (45.5)
Lesion length, mm, mean $\pm$ SD	190.61 $\pm$ 111.30
Diameter stenosis, %, mean $\pm$ SD	88.88 $\pm$ 12.43
Calcification classification	
2 (focal)	6 (18.2)
3 (mild)	6 (18.2)
4 (moderate)	11 (33.3)
5 (severe)	10 (30.3)
Type of balloons used for predilation (n=52)	
High pressure noncompliant	15 (28.8)
Semicompliant	37 (72.2)
Diameter of Selution balloons used (n=54)	
2.0	3 (5.6)
2.5	16 (29.7)
3.0	17 (31.5)
3.5	18 (33.3)

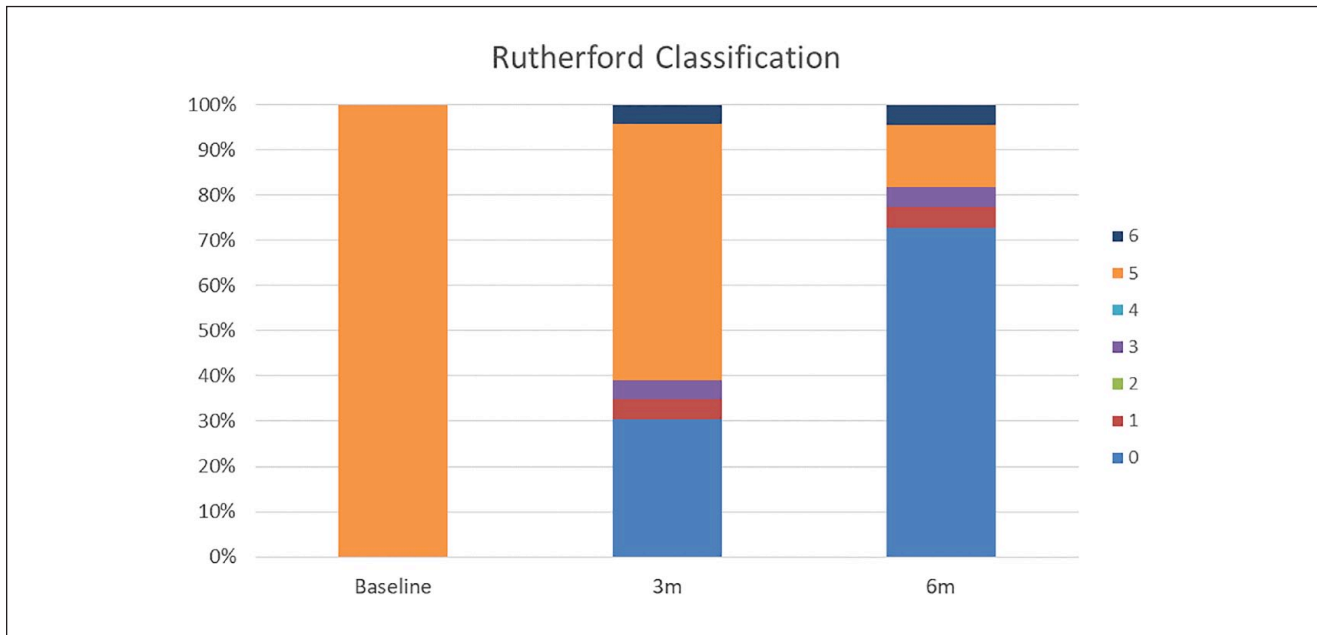
Abbreviation: TASC, TransAtlantic InterSociety Consensus.

prolonged inflation time especially for more calcified and long total occlusive lesions.<sup>34,35</sup> In PRESTIGE, both primary investigators used a 180-second preparatory CBA inflation time and judicious use of longer length balloons to minimize the risk of dissection. Those vessels (10/25 patients), which had severe calcification were deliberately predilated with a high-pressure noncompliant balloon. High pressure generated by these balloons may reduce the elastic recoil phenomena associated with normal semicompliant balloons by overcoming the rigidity the calcium places on

the vessel wall. Doing so affords perhaps greater luminal gain and may allow more effective transfer of sirolimus into all layers of the artery wall. It was previously shown that the use of these balloons in treating highly complex infrapopliteal atherosclerotic lesions is safe and highly efficacious with a primary tibial patency rate of 73% at 6 months and a 88% wound healing rate at 1 year.<sup>16</sup> The institution of a rigid policy of performing prolonged predilatation using longer balloons to reduce recoil, selective use of dedicated high-pressure noncompliant balloons for the more severely



**Figure 2.** (A) Cumulative incidence of target lesion revascularization (TLR) events estimated from competing events that preclude TLR, that is, amputation and death. (B) Survival probability for amputation-free survival (AFS) and death estimated using Kaplan-Meier analysis.



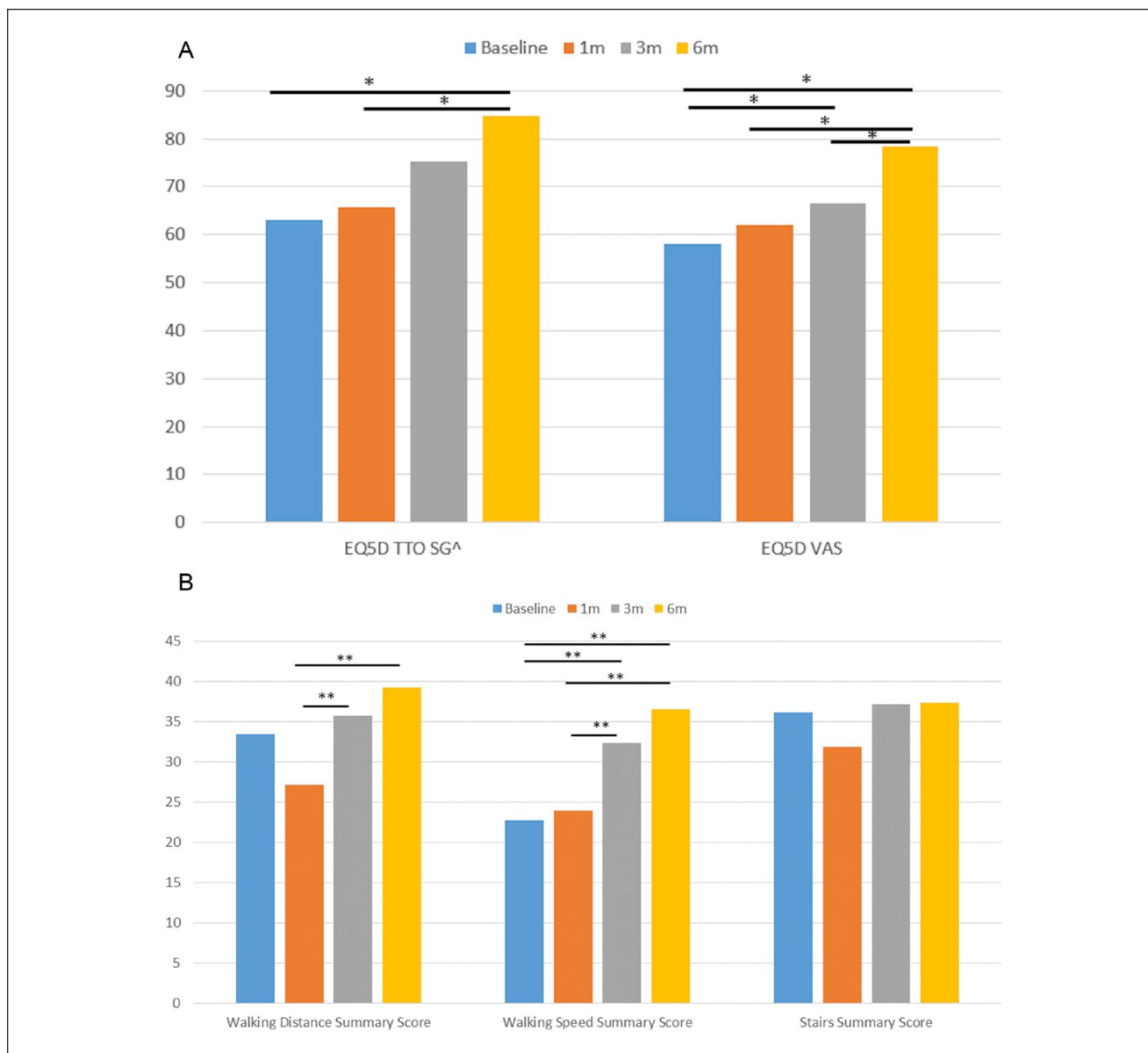
**Figure 3.** Rutherford classification at baseline, 3 months, and 6 months. From 25/25 subjects assessed as (100%) Rutherford 5 at baseline, the percentage decreases to 56.5% at 3 months and finally 13.6% at 6 months. Eighteen of 25 (81.8%) of subjects have shown improvement by at least 1 category by 6 months.

calcified tibial lesions and addition of sirolimus elution to offset the NIH effect from the barotrauma caused, has comparatively improved target lesion primary patency rate to 80% at 6 months with a similar profile of patients with CTLI. This difference may be small overall and one of the reasons could be explained by undersizing of the tibial vessel with the preparatory balloon as shown by Mustapha’s group<sup>36</sup> who are proponents of intravascular ultrasound

imaging during PAD endovascular interventions for more accurate estimation.

Although this is the first report of using sirolimus to minimize the NIH effect in the tibial vessels in the setting of CLTI, there has also been a recent publication (Selution 50) using the same sirolimus-coated balloon in the femoropopliteal region but only in the setting of intermittent claudication (Rutherford 2 and 3).<sup>37</sup> Selution 50 was the

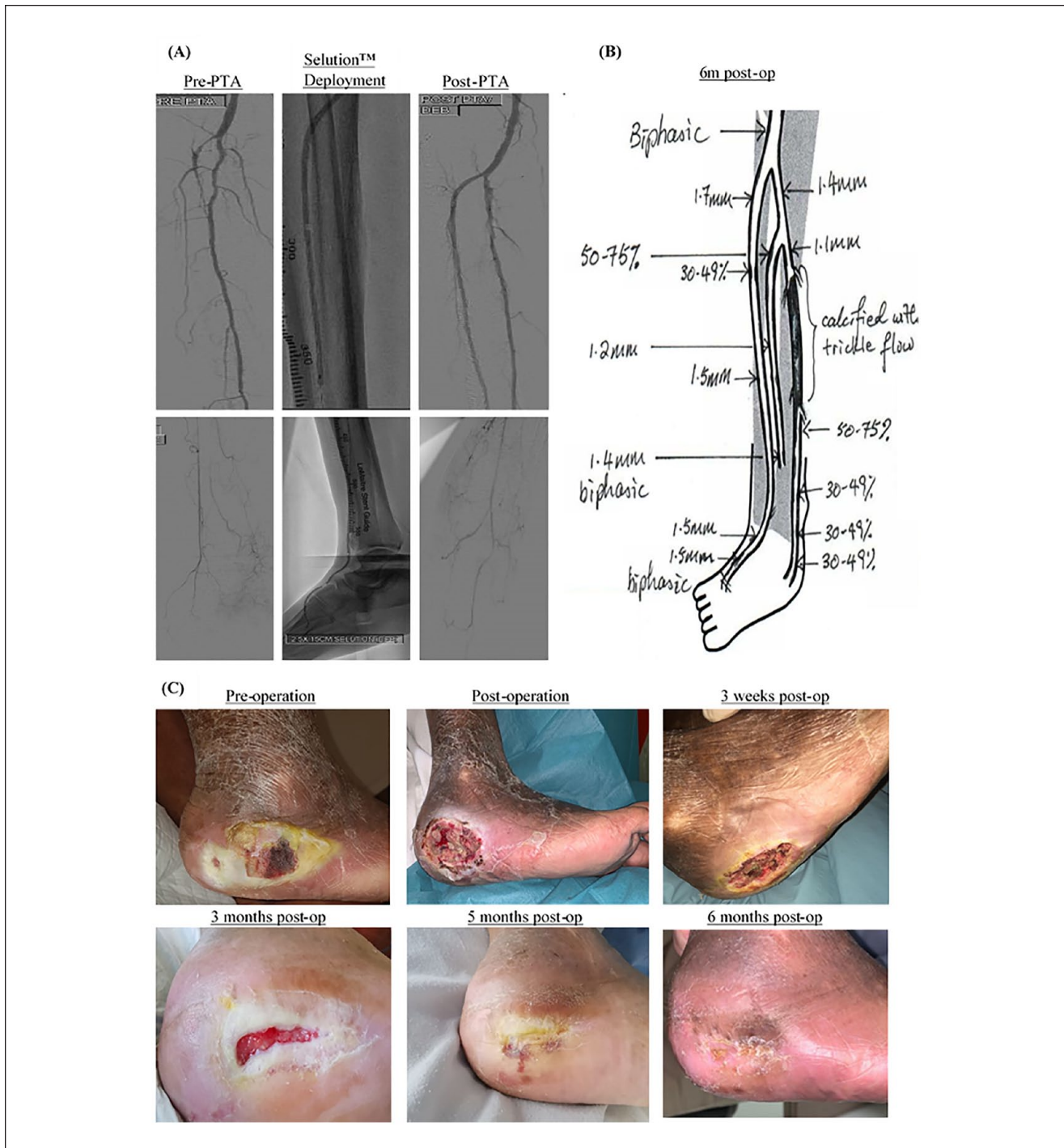




**Figure 4.** EQ5D and Walking Impairment Questionnaire. (A) EQ5D TTO SG: EuroQol-5 Dimension Time Trade-Off Singapore; EQ-5D VAS: EuroQol-5 Dimension Visual Analogue Scale; Significant at  $p < 0.05$  when compared with baseline values. \*\* $p \leq 0.05$ . <sup>^</sup>Values for EQ-5D TTO SG have been scaled up by a factor of 100 for illustrative purposes. (B) Significant at  $p < 0.05$  when compared with baseline values; \*  $p \leq 0.05$ .

first in human study, which demonstrated not only that the balloon had an excellent safety profile with the only major adverse event being a single reintervention, but also it was highly efficacious in reducing angiographic late lumen loss. The rate of primary patency by duplex ultrasound was 88.4%, and freedom from angiographic binary restenosis was 91.2% at 6 months. What was striking from the results was the positive remodeling of the artery in 10 patients as indicated by the negative late lumen loss values at 6 months. This may be related to the

fact that sirolimus becomes equally distributed within all the layers of the arterial wall, which in contrast to paclitaxel has a predisposition to only accumulate in the adventitia and is thought to play an inferior role in retarding the restenotic cascade.<sup>11</sup> Aneurysm formation following sirolimus coated stent placement in the coronary vasculature has also been reported,<sup>38</sup> albeit rarely, but this phenomenon may be advantageous in the setting of occlusive disease when vessel expansion may improve blood flow to the ischemic foot.



**Figure 5.** An example of the wound healing course of a PRESTIGE enrolled patient. The patient presented with a 2-month history of a worsening left heel wound with a long occlusion of the left anterior tibial artery (ATA) and disease within the left dorsalis pedis artery (A). There was minor disease within the left peroneal artery (PA). The posterior tibial artery was completely occluded with no target vessel to aim for distally. Decision to open the left ATA. Once the chronic total occlusion (CTO) was crossed from an antegrade position, the lesion was prepared with 3 mm × 240 mm (proximally) and 2.5 mm × 80 mm (distally) high-pressure noncompliant plain balloons (Jade, OrbusNeich, Hong Kong) each for a duration of 3 minutes. Solution SLR DEB (drug-eluting balloon) (3 mm × 150 mm × 2 and 2.5 mm × 150 mm) were then applied to cover the whole lesion length from origin of ATA to DPA each for 2-minute duration to allow maximal drug transfer to the arterial wall. The PA was predilated with a 3-mm high-pressure noncompliant balloon and drugged with a 3 mm × 150 mm Solution SLR DEB. No slow phenomenon was noticed on the angiogram run afterward in either vessel. (B) The 6-month arterial duplex scan showing patency of both the ATA and PA each with a biphasic signal. (C) The wound healing course of the heel ulcer, which had completely healed by 3 months and had stayed closed at the 6-month follow up.

## Limitations

Major limitations were its single-arm, single-center, non-randomized nature, and relatively small sample size. There was no comparator control arm, and no quantitative angiographic measurements were performed to look at exact lesion lengths, reference vessel diameters, and luminal gain post angioplasty for each tibial lesion. Furthermore, inflow SFA/popliteal lesions were only treated with plain old balloon angioplasty and ideally these would have been treated with appropriate-sized DEB if available, although no TLR were for inflow lesions. Core lab adjudication for vessel follow-up patency was not employed. A repeat angiogram would have been difficult logistically to perform in a frail population of CLTI patients, who tend to have a high incidence of chronic kidney disease and if unwarranted clinically, may be difficult to justify for research purposes. Duplex ultrasound imaging at follow-up, although a convenient tool has its drawbacks—the peak systolic velocity ratio criterion of  $<2.5$  to determine the vessel patency is more acceptable in femoropopliteal intervention but there is no consensus regarding accuracy for below-the-knee or below-the ankle disease.

Furthermore, SGH is an experienced center for diabetic foot salvage in CLTI patients, with established multi-disciplinary protocols for endovascular revascularization and wound care, which may limit the reproducibility elsewhere. However, the patients included in this study are representative of daily clinical practice, where we deal with Asian CLTI patients who have long complex occlusive atherosclerotic lesions and heavy wall calcification.

## Conclusions

The pilot PRESTIGE study has shown that the Selution SLR DEB is safe and efficacious, at least in the short term, in treating complex infra-popliteal atherosclerotic lesions in a frail population of CLTI patients with a high incidence of DM and ESRF. We have demonstrated high technical and clinical success, 6-month target lesion tibial patency and AFS, at least comparable to the current below the knee paclitaxel literature. Further studies are required to confirm these results in larger cohorts of patients with more precise imaging protocols. A subsequent report is planned for this study through 1 and 2 years.

## Authors' Note

The study protocol and early results were presented as an oral presentation at the LINC meeting, Leipzig, Germany, January 28–31, 2020.

## Declaration of Conflicting Interests





The author(s) declared the following potential conflicts of interest with respect to the research, authorship, and/or publication of this

article: TYT has received honoraria from Biotronik, Philips, iVascular, Medtronic and Bard BD. His institution has received research and clinical trial study funds from Abbott Vascular, Bard BD, Biotronik, Boston Scientific, iVascular, M. A. MedAlliance and Medtronic.

## Funding

The author(s) disclosed receipt of the following financial support for the research, authorship, and/or publication of this article: The Manufacturer (M.A. MedAlliance SA) has provided an unrestricted research grant to defray costs of running the study and analyzing the data.

## ORCID iDs

Charyl Yap  <https://orcid.org/0000-0002-8606-0842>  
 Shereen Xue Yun Soon  <https://orcid.org/0000-0003-3057-5983>  
 Sze Ling Chan  <https://orcid.org/0000-0003-4272-4595>  
 Hsien Ts'ung Luke Tay  <https://orcid.org/0000-0002-0276-1722>

## Supplemental Material

Supplemental material for this article is available online.

## References

1. Fowkes FG, Rudan D, Rudan I, et al. Comparison of global estimates of prevalence and risk factors for peripheral artery disease in 2000 and 2010: a systematic review and analysis. *Lancet*. 2013;382:1329–1340.
2. Conte MS, Bradbury AW, Kolh P, et al. Global vascular guidelines on the management of chronic limb-threatening ischemia. *Eur J Vasc Endovasc Surg*. 2019;58(1S):S1–S109. e33.
3. Mustapha JA, Finton SM, Diaz-Sandoval LJ, et al. Percutaneous transluminal angioplasty in patients with infrapopliteal arterial disease: systematic review and meta-analysis. *Circ Cardiovasc Interv*. 2016;9:e003468.
4. Baumann F, Fust J, Engelberger RP, et al. Early recoil after balloon angioplasty of tibial artery obstructions in patients with critical limb ischemia. *J Endovasc Ther*. 2014;21:44–51.
5. Weintraub WS. The pathophysiology and burden of restenosis. *Am J Cardiol*. 2007;100:3K–9K.
6. Baumann F, Bloesch S, Engelberger RP, et al. Clinically-driven need for secondary interventions after endovascular revascularization of tibial arteries in patients with critical limb ischemia. *J Endovasc Ther*. 2013;20:707–713.
7. Giannopoulos S, Varcoe RL, Lichtenberg M, et al. Balloon angioplasty of infrapopliteal arteries: a systematic review and proposed algorithm for optimal endovascular therapy. *J Endovasc Ther*. 2020;27:547–564.
8. Iida O, Soga Y, Kawasaki D, et al. Angiographic restenosis and its clinical impact after infrapopliteal angioplasty. *Eur J Vasc Endovasc Surg*. 2012;44:425–431.
9. Marx SO, Marks AR. Bench to bedside: the development of rapamycin and its application to stent restenosis. *Circulation*. 2001;104:852–855.
10. Abizaid A. Sirolimus-eluting coronary stents: a review. *Vasc Health Risk Manag*. 2007;3:191–201.

11. Wessely R, Schomig A, Kastrati A. Sirolimus and paclitaxel on polymer-based drug-eluting stents: similar but different. *J Am Coll Cardiol*. 2006;47:708–714.
12. Salisbury AC, Li H, Vilain KR, et al. Cost-effectiveness of endovascular femoropopliteal intervention using drug-coated balloons versus standard percutaneous transluminal angioplasty: results from the IN.PACT SFA II Trial. *JACC Cardiovasc Interv*. 2016;9:2343–2352.
13. Caradu C, Lakhlifi E, Colacchio EC, et al. Systematic review and updated meta-analysis of the use of drug-coated balloon angioplasty versus plain old balloon angioplasty for femoropopliteal arterial disease. *J Vasc Surg*. 2019;70:981–995.e10.
14. Katsanos K, Spiliopoulos S, Kitrou P, et al. Risk of death following application of paclitaxel-coated balloons and stents in the femoropopliteal artery of the leg: a systematic review and meta-analysis of randomized controlled trials. *J Am Heart Assoc*. 2018;7:e011245.
15. Katsanos K, Spiliopoulos S, Kitrou P, et al. Risk of death and amputation with use of paclitaxel-coated balloons in the infrapopliteal arteries for treatment of critical limb ischemia: a systematic review and meta-analysis of randomized controlled trials. *J Vasc Interv Radiol*. 2020;31:202–212.
16. Tang TY, Lee SQW, Chan SL, et al. Utility of a novel high pressure non-compliant balloon for tibial atherosclerotic lesions in Asian patients with chronic limb threatening ischaemia. *Vasa*. 2020;49:475–482.
17. Tang TY. How low can you go? SELUTION SLR™ tibial artery drug-coated balloon angioplasty in the setting of CLTI. Paper presented at: LINC 2020. Leipzig, Germany.
18. Rutherford RB, Baker JD, Ernst C, et al. Recommended standards for reports dealing with lower extremity ischemia: revised version. *J Vasc Surg*. 1997;26:517–538.
19. Tay WL, Chong TT, Chan SL, et al. Two-year clinical outcomes following lower limb endovascular revascularisation for chronic limb threatening ischaemia at a tertiary Asian vascular centre in Singapore. *Singapore Med J*. Published online July 16, 2020. doi:10.11622/smedj.2020104
20. Norgren L, Hiatt WR, Dormandy JA, et al. Inter-Society Consensus for the management of peripheral arterial disease (TASC II). *J Vasc Surg*. 2007;45(suppl S):S5–S67.
21. Dattilo R, Himmelstein SI, Cuff RF. The COMPLIANCE 360 degrees trial: a randomized, prospective, multicenter, pilot study comparing acute and long-term results of orbital atherectomy to balloon angioplasty for calcified femoropopliteal disease. *J Invasive Cardiol*. 2014;26:355–360.
22. Rabin R, de Charro F. EQ-5D: a measure of health status from the EuroQol Group. *Ann Med*. 2001;33:337–343.
23. McDermott MM, Liu K, Guralnik JM, et al. Measurement of walking endurance and walking velocity with questionnaire: validation of the walking impairment questionnaire in men and women with peripheral arterial disease. *J Vasc Surg*. 1998;28:1072–1081.
24. RCT. R: A language and environment for statistical computing. R Foundation for Statistical Computing, Vienna, Austria. <https://www.R-project.org/>
25. Mills JL Sr, Conte MS, Armstrong DG, et al. The Society for Vascular Surgery Lower Extremity Threatened Limb Classification System: risk stratification based on wound, ischemia, and foot infection (WIFI). *J Vasc Surg*. 2014;59:220–234.e1-2.
26. Schanzer A, Hevelone N, Owens CD, et al. Technical factors affecting autogenous vein graft failure: observations from a large multicenter trial. *J Vasc Surg*. 2007;46:1180–1190.
27. Liistro F, Porto I, Angioli P, et al. Drug-eluting balloon in peripheral intervention for below the knee angioplasty evaluation (DEBATE-BTK): a randomized trial in diabetic patients with critical limb ischemia. *Circulation*. 2013;128:615–621.
28. Mustapha JA, Brodmann M, Geraghty PJ, et al. Drug-coated vs uncoated percutaneous transluminal angioplasty in infrapopliteal arteries: six-month results of the Lutonix BTK trial. *J Invasive Cardiol*. 2019;31:205–211.
29. Zhou Y, Lin S, Zhang Z, et al. A network meta-analysis of randomized controlled trials comparing treatment modalities for infrapopliteal lesions in critical limb ischemia. *Ann Vasc Surg*. 2019;60:424–434.
30. Wu R, Tang S, Wang M, et al. Drug-eluting balloon versus standard percutaneous transluminal angioplasty in infrapopliteal arterial disease: a meta-analysis of randomized trials. *Int J Surg*. 2016;35:88–94.
31. Xiao Y, Chen Z, Yang Y, et al. Network meta-analysis of balloon angioplasty, nondrug metal stent, drug-eluting balloon, and drug-eluting stent for treatment of infrapopliteal artery occlusive disease. *Diagn Interv Radiol*. 2016;22:436–443.
32. Ipema J, Huizing E, Schreve MA, et al. Editor's Choice. Drug coated balloon angioplasty vs. standard percutaneous transluminal angioplasty in below the knee peripheral arterial disease: a systematic review and meta-analysis. *Eur J Vasc Endovasc Surg*. 2020;59:265–275.
33. Boitet A, Grassin-Delyle S, Louedec L, et al. An experimental study of paclitaxel embolisation during drug coated balloon angioplasty. *Eur J Vasc Endovasc Surg*. 2019;57:578–586.
34. Horie K, Tanaka A, Taguri M, et al. Impact of prolonged inflation times during plain balloon angioplasty on angiographic dissection in femoropopliteal lesions. *J Endovasc Ther*. 2018;25:683–691.
35. Rhee TM, Lee JM, Shin ES, et al. Impact of optimized procedure-related factors in drug-eluting balloon angioplasty for treatment of in-stent restenosis. *JACC Cardiovasc Interv*. 2018;11:969–978.
36. Pliagas G, Saab F, Stavroulakis K, et al. Intravascular ultrasound imaging versus digital subtraction angiography in patients with peripheral vascular disease. *J Invasive Cardiol*. 2020;32:99–103.
37. Zeller T, Brechtel K, Meyer DR, et al. Six-month outcomes from the first-in-human, single-arm SELUTION Sustained-Limus-Release Drug-Eluting Balloon trial in femoropopliteal lesions. *J Endovasc Ther*. 2020;27:683–690.
38. Zbinden R, Eshthardi P, Cook S. Coronary aneurysm formation in a patient early after everolimus-eluting stent implantation. *J Invasive Cardiol*. 2008;20:E174–E175.